



Newsletter

Volume 2, Issue 3

September 1997

Quarterly Publication of the **Arizona Veterinary Diagnostic Laboratory** and Cooperative Extension

From the Director:

Work on the I-10 frontage road has been completed. Once all walk-through inspections by ADOT (and resulting corrections by the contractor) are completed in a few weeks, we should have direct access to I-10. Call us at (520)621-2356 for the status of the access to the AzVDL; especially, those of you coming from outside the Tucson area who may be less familiar with the exact location of the laboratory.

Carlos Reggiardo, Director

Nitrate Poisoning in Ruminants

Arizona veterinarians having practices that include ruminant animals should take note of several cases of nitrate poisoning reported in this newsletter. All animals that we have diagnosed as dying of nitrate poisoning consumed weedy, poor-quality hay or irrigated pasture contaminated with pigweed. The cases that have occurred so far have been from southeastern Arizona.

Ruminants are most susceptible to nitrate poisoning because of the greater efficiency of rumen microorganisms in converting nitrate to the more toxic nitrite form. The horse is less susceptible than the ruminant, probably because microorganisms in the hindgut are less efficient in converting nitrate, making poisoning less likely, but still possible. When absorbed, nitrite converts hemoglobin to methemoglobin, which renders it incapable of transporting oxygen and results in signs of hypoxia. Death occurs fairly rapidly in ruminants in severe cases. Clinical signs vary according to the degree of methemoglobin formation. Nitrate-poisoned animals, if examined while moribund or recently dead, may have chocolate-colored blood which does not clot. It is reported that in animals dead longer than 5 hours the typical discoloration of the blood fades. It is our experience that discoloration of the blood is not commonly observed at necropsy due to the substantial post-mortem interval between death and necropsy that is typical of bovine case material. There are no other diagnostic necropsy lesions. Nitrate poisoning in the bovine must be differentiated from urea poi-

soning, cyanide poisoning, acute bovine pulmonary emphysema, and sodium chlorate poisoning.

Animals dying following consumption of weedy forage can be evaluated for nitrate poisoning by submitting (in order of preference) aqueous humor from the eye, cerebrospinal fluid, serum or heparinized whole blood, or rumen contents. Rumen contents should be collected within 2 hours of death and be refrigerated or frozen immediately to inhibit microbial activity. Suspicious forage should be submitted for testing as well. Dried forage retains its toxic potential.

Good reviews of nitrate poisoning and its effects on livestock are in recent articles in the *Compendium on Continuing Education*: volume 19, Number 5, May 1997, pages 643-648 and the 3rd edition of *Clinical and Diagnostic Veterinary Toxicology*, pages 460-467. *T. H. Noon*

*Illustration reproduced with permission from Ervin M. Schmutz, Barry N. Freeman and Raymond E. Reed's Livestock Poisoning Plants of Arizona, The University of Arizona Press 1968©

In this issue:

From the director	page 1
Livestock nitrate toxicity	page 1
Diagnostic case update - June to Aug.	page 2
Vesicular stomatitis update	page 5

Diagnostic Update

The following are selected samples of cases submitted to the AzVDL during the summer months of June, July and August.



Bovine

Nitrate poisoning was diagnosed in a one year old, 600 lb., crossbred calf that was 1 of 5 to die in a herd of 100. The calves would die within 1-6 hours of being fed poor quality alfalfa hay. Bloating was not observed. The affected calves were uncoordinated and would “stagger” and died without a struggle. The calves had been fed “weedy” hay that was the first cutting from a field that had been abandoned for “5-10 years”. A hay sample submitted with the case contained a considerable amount of weedy plant material resembling redroot pigweed (carelessweed, *Amaranthus* sp.). When present as a hay contaminant, the plant can be presumptively identified by the presence of fairly large, coarse stems streaked with red. Suspect weeds from the hay sample were strongly positive for nitrate using the diphenylamine test. Quantitative analysis revealed ~5% nitrate on a dry weight basis (>1% nitrate d.w. is toxic to ruminants). Ocular fluid (aqueous humor) from the dead calf was also strongly positive for nitrate.

Toxic levels of nitrate (for ruminants) were present in a forage sample from irrigated pasture submitted to the AzVDL that was unrelated to the previous case. Unexplained death losses had occurred in calves grazing the pasture. The pasture forage contained 2% nitrate d.w. Pigweed growing in the forage in the same field contained 4% nitrate d.w. (>1 % d.w. is likely to be toxic to ruminants).

Nitrate poisoning was diagnosed in another herd of cattle from southeastern Arizona. From a herd of 50, 8 animals died suddenly after consuming a newly purchased batch of baled hay. On close inspection, the baled hay contained numerous weed stems compatible with pigweed. The stems contained approximately 4.6% nitrate. Ocular fluid from one of the dead animals contained >200 ppm nitrate.

Clostridial abomasitis (Braxy) was diagnosed in a 1 day old Holstein calf from a calf ranch found dead. Necropsy lesions included diffuse edema, necrosis, and hemorrhage of the abomasal mucosa from which anaerobic cultures yielded a mixed clostridial flora. The etiologic agent, *Clostridium septicum*, was identified by fluorescent antibody-stained imprints of abomasal mucosa. The pathogenesis of Braxy in calves is incompletely understood but is thought, at least in some countries (e.g. the U.K.), to be associated with the ingestion of cold or frozen milk or feed.

Multiple **subcutaneous abscesses** were diagnosed in a 250

pound Holstein steer presented for necropsy. Other calves were similarly affected. Large subcutaneous swellings were present in the subcutis of the anterior sternal area and the subcutis of the left stifle. Cultures of the abscesses yielded no bacterial growth. However, gram's stained sections of abscess wall revealed a few bacteria suggesting a corynebacterial (most likely *Corynebacterium pyogenes*) infection. Corynebacterial abscesses are common in cattle, since corynebacteria are ubiquitous in the bovine environment. In this case, trauma from an environmental source (i.e. calf-rearing crates) was suspected as an initiating cause. The calf was also affected with a **bronchointerstitial pneumonia** of the apical and cardiac lobes of both lungs, from which **mycoplasma** were isolated.

Hemophilus somnus was isolated from the lung tissue of a 6 month old, crossbred steer with bronchopneumonia. In our experience *Haemophilus somnus* is not as common a cause of pneumonia in Arizona as it is in more northern latitudes.

Acute **suppurative cholangiohepatitis** was the diagnosis in a dairy cow. The cow presented with an acute illness characterized by pyrexia, weakness and dehydration. On post-mortem examination, there was a pale liver from which *E. coli* was isolated. In our experience cholangiohepatitis due to ascending infection is less common in the bovine than in the equine.

Samples of lung from 4 feedlot steers which had been in feed for periods of 70 to 100 days were received for histologic examination. The feedyard had been experiencing a continuous and abnormally high mortality in heavier calves for quite some time. Lesions of **Acute Interstitial Pneumonia** (acute bovine emphysema and edema) were observed in all 4 lung samples. Causes of interstitial pneumonia in feedlots are largely unknown. In this case, the levels of liver selenium in seven affected steers ranged from 0.09-0.14 ppm, levels much lower than the “adequate” range of 0.25-0.50 ppm. Although the exact association, if any, of selenium and the pulmonary lesions is unknown, a selenium deficiency could conceivably aggravate oxidative lesions to alveolar epithelium and/or predispose to the secondary pulmonary infections usually observed in these conditions.

Respiratory infections in young dairy calves are usually produced by *Pasteurella multocida* and *Mycoplasma* spp. Clinical disease and/or significant nasal shedding of these agents does not happen in most cases until the calves are 3 or 4 weeks of age or older. Widespread clinical disease and massive shedding of *Pasteurella multocida* and *Mycoplasma* spp. in almost 100% of calves as young as 4 days of age, were recently diagnosed in one of two dairy herds owned by the same company. Management and nutritional programs were identical in both herds, but significant disease and nasal shedding of bacterial

pathogens were not observed in the second herd until 3 to 4 weeks later. The quality of housing was the only significant difference between both herds. Poor ventilation was identified as the reason for the excessive level of respiratory disease in the first herd. This case illustrates the importance of often neglected environmental factors in the occurrence of neonatal disease in the calf.



Avian

An adult budgie was part of a flock of 30 in which 4 died. At necropsy there was moderate bilateral atrophy of the pectoral musculature and a large whitish canker-like lesion was firmly attached to the pharyngeal mucosa. Multiple smaller, similar lesions were evident on esophageal mucosa distal to the lesion. Considerable mucus was present in the esophageal lumen. Cultures of the pharyngeal lesion were positive for trichomonads and the microscopic lesions were typical. Although usually thought of as being a disease of columbiform birds (dove, pigeons), **trichomoniasis** has been reported in a variety of other birds. Occasional cases in non-columbiform birds are diagnosed at the AzVDL.

Polyomavirus infection was diagnosed in a 3 month old Moluccan cockatoo. Necropsy revealed a swollen liver. Microscopic examination revealed intranuclear inclusions compatible with polyomavirus in epithelial cells of collecting tubules of kidney as well as in bronchiolar epithelium of lung.

Avian **polyomavirus** infection was also diagnosed in an 8 week old Macaw chick. Gross necropsy findings included petechial and ecchymotic hemorrhages in the subcutis and epicardium. In this case a different lesion distribution was seen with characteristic intranuclear inclusion bodies found in the liver and spleen.

Several examples of **neoplasia in pet birds** were seen: A renal carcinoma arising in the right kidney was found in a parakeet received for necropsy. Metastasis to the liver was present. A one and one half year old, male cockatiel euthanized and presented for necropsy was diagnosed with multicentric lymphoma affecting the lungs, liver, pancreas, myocardium mesentery, kidney, intestines and testes. A 2 year old, male parakeet with a history of emaciation, ascites and erratic heart rate had a pancreatic adenocarcinoma with transcoelomic implantation on the serosa of the intestine, mesentery and body wall.

Two Trumpeter hornbill chicks with clinical signs of head tilt and torticollis had cerebral **aspergillosis**. The brain lesions were yellow caseous foci within which were branching septate fungal hyphae. Acute, necrotizing **Aspergillosis** of the lung and brain was also diagnosed in a goose chick.

A **triple mycotic infection** was diagnosed in an adult mini macaw. An acute zygomycetic pneumonia produced by a Mucor-like fungus, a chronic pulmonary aspergillosis and a chronic candidiasis of the cloaca coexisted in the same animal. There was also a chronic hepatitis and polyserositis. Chlamydiosis was suspected as the immunosuppressive condition precipitating the multiple mycotic infections, although it could not be confirmed by isolation of the agent.

Disseminated **Mycobacteriosis** were diagnosed in a Red Lored amazon and in a Gouldian finch submitted by two breeders for necropsy. Splenomegaly was the only gross lesion observed in the finch, but numerous clear nodules were observed in the lung, spleen, liver and the intestines of the Red Lored amazon.



Canine

A 13 year-old Westie that had been treated for a refractory, "**chronic non-productive cough**" was euthanized and presented for necropsy. An ECG interpretation submitted as part of the history reported a "possible early sinus node disease" as there were "pauses of sinus arrest or block". The dog had also been treated for chronic atopy. Necropsy revealed a small amount of ascitic fluid, a somewhat enlarged liver, and congested, edematous lungs. Histopathologic evaluation revealed a mild chronic bronchiolitis, a moderate tracheitis, and mild inflammation of the right atrium of heart. It was concluded that a multifactorial etiology (i.e. allergic bronchiolitis, tracheitis, and possible cardiac insufficiency) was responsible for the coughing.

Acute gastric dilatation was diagnosed as the cause of death in a 5 year old Great Pyrenees weighing 100 pounds. The dog had been observed to be "fine" at 11 pm the night before then was found dead at 5 am by its owners.

Granulomatous encephalitis was diagnosed in an 8 year old neutered female shepherd mix canine. Two days after surgery for a toe amputation, the dog "started circling to the left". The dog continued to deteriorate. The next day she was unable to walk and became comatose and non-responsive with constricted pupils. Microscopic lesions were typical of granulomatous encephalitis, an idiopathic disease of dogs.

Strychnine toxicosis was diagnosed in a 2 year-old Labrador mix canine presented for necropsy. Another dog on the same premises had experienced a sudden onset of seizures but subsequently recovered. The stomach of the dead dog contained a meat-type baitlike material along with a few fragments of bone. Testing of the stomach contents for strychnine was positive (by TLC). As reported in the March, 1997 AzVDL newsletter, strychnine is the toxicant of choice for the malicious poisoning in pets in our case material.

A 9 month old Labrador retriever cross dog died following a clinical history of nasal/ocular discharge and ataxia. It was one of 21 dogs in a “foster home” of which 10 were sick and 4 had died. Necropsy revealed **canine distemper virus** infection and *Nocardia* sp. septicemia with microabscesses in the brain and kidneys. A 9 week old Shepherd cross puppy from the same premises was received for necropsy 3 days later. The puppy had a 24 hour history of vomiting, diarrhea and fever (105° F). Necropsy revealed intestinal infection with **canine parvovirus**, group B *Salmonella* and *Candida* sp.

Mesothelioma of the right atrial epicardium was the cause of pericardial effusion, cardiac tamponade and death in an 11 year old, spayed female, mixed breed dog. The dog had presented with an acutely painful and distended abdomen and died shortly thereafter. At necropsy, the peritoneal, thoracic and pericardial cavities were filled with red tinged fluid. The heart was contracted. The epicardial surface of the heart contained a filiform, grey, soft mass protruding into the pericardial sac.



Feline

Lesions compatible with **Feline Ischemic Encephalopathy** were diagnosed in a cat that had been euthanized 2 days after being presented to a veterinarian “acting strange, foaming at mouth”. The cat had been vocalizing and hypersalivating, was underweight, and had a “scruffy haircoat”. FeLv/FIV serology was negative. There were no gross lesions. Neuronal necrosis and gliosis with some perivascular cuffing were the most significant microscopic lesions. A rabies check was negative. Brain acetylcholinesterase activity was within acceptable limits.

Pyogranulomatous encephalitis due to infection by an unidentified fungus was diagnosed in a 2 year neutered male domestic shorthair feline that had shown unspecified “neurological signs”. The cat had bitten its owner on the finger. No gross lesions were evident at necropsy. A rabies check of brain tissue was negative. In addition to inflammatory changes typical of pyogranulomatous inflammation, special staining of brain sections for fungi revealed fungal hyphae scattered throughout the most severely affected areas. A bone marrow imprint from the cat was also positive for feline leukemia virus.

Pyothorax due to infection by a mixed population of strict anaerobic bacteria was diagnosed in a 5 year-old neutered female domestic long-hair feline. The cat was found “dehydrated, weak, and semicomatose”. At necropsy, the thorax was filled with malodorous, brown, turbid fluid from which the mixed population of anaerobic bacteria was isolated. Both spleen and bone marrow from the cat were negative for FeLv.

Necrotizing myositis and cellulitis with bacterial embolization, necrosis and vascular thrombosis of the lung, adrenal gland, skin and heart caused by *Streptococcus canis* (Lancefield group G) was the cause of death in an 8-week-old, female Siamese kitten. The history was that of an acute onset of soft tissue swelling, anorexia and lethargy. Endometritis and septicemia due to this agent had been previously diagnosed in a queen. Neonatal streptococcosis is occasionally a problem in catteries and may be epizootic. The organism is carried in the nose, mouth, genitals and on the skin of cats. Kittens are infected from vaginal secretions or through the umbilicus when the queen bites through the umbilical cord. The organism enters through the umbilical vessels and spreads to a variety of body sites including the liver, spleen, lung, kidneys and skeletal muscle. The disease occurs more commonly in litters born to younger queens. Older queens become immune and provide passive protection for their kittens. This organism is also the most commonly isolated bacterium from skin and lymph node abscesses, metritis, and mastitis in cats.



Wildlife

Lead intoxication was diagnosed as the cause of death in a wild Golden Eagle that had been observed to have eaten 2 ducks around a pond. Atrophy of the pectoral musculature and an absence of body fat were evident at necropsy. Liver tissue contained 8.1 ppm (> 8 ppm toxic in waterfowl). Other causes of death were ruled out.

Severe enteric **nematodiasis** due to *Acanthocephala* (thorny headed worms) was diagnosed in a juvenile Red-tailed hawk submitted for necropsy. The bird had died after being observed to be ill by a rehabilitator the previous day. There was bilateral atrophy of the pectoral musculature and numerous nematodes were present in the lumen of the small intestine. No other lesions were seen. Other causes of death were ruled out. To the best of our knowledge *Acanthocephala* infections are an unusual finding in this species.

A unique form of **salmonellosis** was recently seen in 3 blackbirds from the Safford area. Large numbers of these birds were dying. A group B *Salmonella* sp. was isolated from the tissues of all three. The birds had multifocal, yellow, fibrinonecrotic plaques over ulcerated mucosa in the esophagus and colon. Microscopically, colonies of rod-shaped bacteria were intermingled with fibrinocellular exudate over ulcerated mucosal epithelium. A similar pattern of fibrinonecrotic esophagitis due to *Salmonella* sp. was recently reported in Pine siskins from northern New Mexico. The esophageal lesions could easily be confused with trichomoniasis. The presence of similar lesions in the intestinal tract and/or liver and cultures will differentiate the two diseases.

Capillaria infection of the esophagus was the cause of emaciation and death in an adult, male Gambel's quail. At necropsy there was a thin white velvety pseudomembrane covering the mucosal surface of the crop. The contents were cloudy fluid. Wet mounts of the crop mucosal surface debris revealed numerous, bipolar eggs.

Parasitic vasculitis with pulmonary hemorrhage due to *Haemoproteus* was diagnosed in an adult, male white-wing dove received for necropsy. The bird was one of approximately fifty doves which died near some wheat and cotton fields in Maricopa county. *Haemoproteus* is a protozoan parasite transmitted by the bite of flies. Mild infections are considered non-pathogenic but fatal infections may occur under conditions of stress or immune deficiency. Intraerythrocytic gametocytes are found in affected birds.

Atoxoplasma (Isospora) sp. infection was the cause of sudden death in a 3 month old sparrow. Protozoa were present in the cytoplasm of large numbers of mononuclear cells infiltrating the liver and heart. Intestinal epithelial cells contained sexual stages of the parasite.



Exotics

Copper deficiency was considered a likely cause of chronic diarrhea and weight loss in a captive-raised herd of Rocky Mountain elk. Necropsy examination was negative for infectious agents. The liver copper was 2.8 ppm (N=20-90 ppm). Copper deficiency secondary to excess molybdenum in the forage, results in a diarrhea and wasting syndrome in cattle. The forage had not been analyzed at the time of this writing.

Disseminated coccidiosis was diagnosed in a 12 year old, male Radiated tortoise. The animal was one of two sick tortoises from a group of eight. Four others had died previously. Clinical signs included anorexia, lethargy, mucoid ocular and nasal discharge, ulcerative conjunctivitis and stomatitis. Histologically, **intranuclear coccidia** were found in epithelium of a variety tissues including liver, pancreas, lung, oral mucous membrane, thyroid gland, intestine, ependyma of the brain, and bile ducts. Many were also seen in reticuloendothelial cell nuclei of the spleen. The parasites were associated with multifocal necrosis and inflammation in the tissues affected.

An unusual case of **Mycobacteriosis** was diagnosed in an Eytons which died suddenly. The infection was almost entirely confined to the adrenal glands, where virtually all adrenal parenchyma had been replaced by mycobacteria-infected macrophages. Extra-adrenal infection was confined to small, localized lesions in spleen and intestines. The massive adrenal infection most likely led to hypoadrenocorticism, causing the death of the animal.

A severe, chronic, granulomatous pneumonia was diagnosed in an adult Boa constrictor. Mycobacterial granulomas had been removed 6 months before from the nose. Although no acid-fast bacteria could be observed in sections of the lung, the Diagnostic Bacteriology Service at NVSL succeeded in isolating *Mycobacterium fortuitum* from the affected lung.

compiled by T. H. Noon, Greg Bradley, Carlos Reggiardo

Comments on Diagnostic Update can be directed to Dr. Greg Bradley via e-mail at: gabrad@ag.arizona.edu

Vesicular Stomatitis Update

The summer of 1997 has seen another significant outbreak of Vesicular Stomatitis in the west. VS was again diagnosed in Arizona, Colorado and New Mexico. Although Arizona has had only one confirmed case of the disease (a serological diagnosis of infection by the New Jersey serotype in one horse in Yavapai county), 89 herds have been diagnosed as positive in Colorado and New Mexico as of 8/22/97. Most of the cases have been produced by the Indiana serotype, which had not been diagnosed in the continental U.S. for over 30 years.

Arizona Veterinary Diagnostic Laboratory

By vehicle the only access to the AzVDL is via Prince Road (I-10 Tucson exit 254), south on La Cholla to the West Campus Agricultural Center Farm. Follow the signs and the dirt road to the facility.

The University of Arizona

College of Agriculture

Department of Veterinary Science/Microbiology

2831 N. Freeway

Tucson, Arizona 85705-5021

Fax: (520) 626-8696 Phone: (520) 621-2356

We welcome any subscriptions, comments or suggestions.

Editor:

Natalie Furrey

Contributing editors:

Greg Bradley

Ted H. Noon

Carlos Reggiardo

Thea Soderquist

Faculty and Staff of the AzVDL

Director: Carlos C. Reggiardo DVM, PhD, Diplomate ACVM

Diagnosticians: Edward J Bicknell DVM, PhD

Greg Bradley DVM, Diplomate ACVP

Ted H. Noon DVM

Raymond E. Reed DVM, Diplomate ACVP

Administrative Staff: Jeannie Barnitz

Necropsy: Melvin Perry

Owen Halferty

Chemistry: Dana Perry Betzer MS

Histology: Esther Kerr MT(ASCP)

Jan Mac Millen HT(ASCP)

Microbiology: Natalie Furrey MT(ASCP)

Virology: Mark Shupe

Thea Soderquist

Adjunct Faculty:

Sharon Dial DVM, PhD

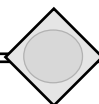
Howard Frederick PhD, PAS

An electronic version of the AzVDL Newsletter can be accessed at: <http://microvet.arizona.edu>

Issued in furtherance of Cooperative Extension work, acts of May 8 and June 30, 1914, in cooperation with the U.S. Department of Agriculture, James A. Christenson, Director, Cooperative Extension, College of Agriculture, The University of Arizona.

The University of Arizona College of Agriculture is an equal opportunity employer authorized to provide research, educational information and other services only to individuals and institutions that function without regard to sex, race, religion, color, national origin, age, Vietnam Era Veteran's status, or disability.

The University of Arizona
Dept of Veterinary Science and Microbiology
Arizona Veterinary Diagnostic Laboratory
2831 N. Freeway
Tucson, AZ 85705-5021



Amaranthus palmeri
(pigweed or carlessweed)*